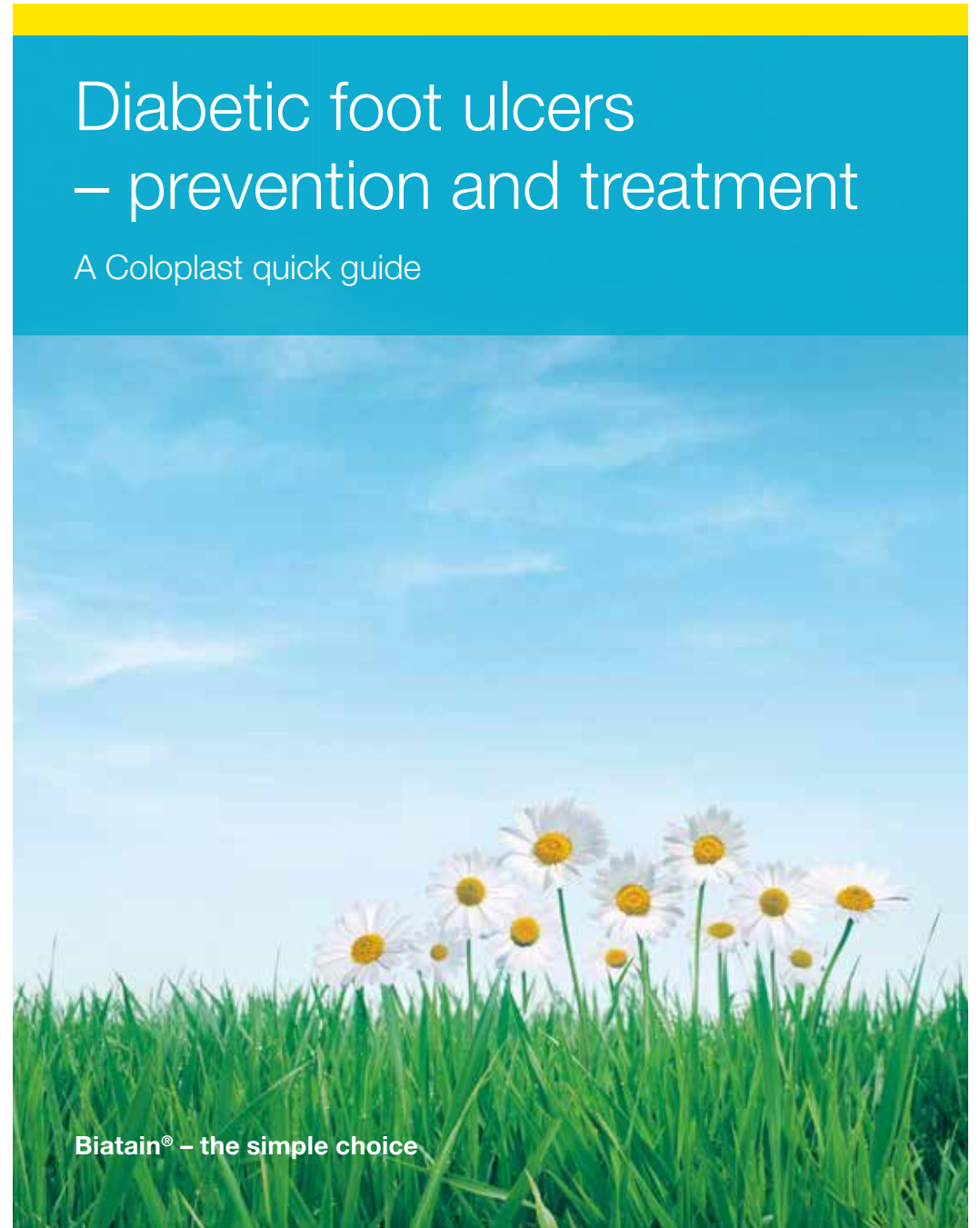


After 30 years in wound care, we at Coloplast believe that absorption is the key to better healing. Our Biatain® portfolio brings superior absorption to daily wound care needs, making Biatain the simple choice for faster healing.

# Diabetic foot ulcers – prevention and treatment

A Coloplast quick guide



# Table of content

Introduction .....	3
The diabetic foot – a clinical challenge .....	5
Pathway to clinical care and clinical evidence .....	6
How to prevent DFU's.....	7
Prevention and education .....	7
Prevention of ulcer formation .....	8
An interprofessional team approach.....	9
The patient's role .....	10
Consider the whole patient to ensure effective care .....	11
How to diagnose and assess a diabetic foot ulcer .....	12
“The VIPS” of diabetic foot management.....	12
Local wound assessment .....	13
Types of neuropathy .....	14
10g monofilament testing .....	15
Areas at risk for neuropathic, ischaemic and neuro-ischaemic ulcers.....	16
Clinical symptoms of neuropathic and ischaemic foot ulcers .....	17
Ulcer assessment .....	18
Wound bed.....	19
Superficial and deep infection symptoms.....	20
Wagner classification .....	21
How to treat a diabetic foot ulcer.....	22
Treatment of diabetic foot ulcers .....	22
Local wound treatment .....	23
Case study .....	24
Coloplast solutions for diabetic foot ulcers .....	26
Coloplast antimicrobial dressings for infected diabetic foot ulcers and ulcers at risk of infection .....	28
Biatain® – superior absorption for faster healing .....	30
Other Coloplast products for diabetic foot ulcers .....	31
References .....	32

## Introduction

Diabetic foot ulcers have a considerable negative impact on patients lives, and are highly susceptible to infection that all too often leads to amputation. It is essential that diabetic foot ulcers receive the best possible wound management. Successfully treating a diabetic foot ulcer requires a comprehensive understanding of the wound: its cause, progression, risk, and treatment. However more than this, it takes a cross functional approach, where the patient also has an active role in the treatment process.

The information provided here is intended as a general guideline. Please consult diabetic foot ulcer guidelines applicable in your area. For further study, please refer to the International Consensus on the Diabetic Foot, 2011.<sup>2</sup>

We hope that this quick guide will help you diagnose, assess and treat diabetic foot ulcers in clinical practice, as well as identify opportunities for prevention and minimising the risk of infection and amputation.

### Developed by

Faculty panel: Dr. Christian Münter, Germany; Professor Patricia Price, UK; Wilma Ruigrok van der Werven, MA, RN, Netherlands; Professor Gary Sibbald, Canada

Review panel: Patricia Coutts, RN, Canada; Mike Edmonds, Consultant Diabetologist, UK; Professor Keith Harding UK; Maria Mousley, AHP, Consultant, Podiatrist, UK

This Coloplast quick guide was updated in March 2012 in collaboration with Dr. Christian Münter.

“I marvel that society would pay a surgeon a fortune to remove a person’s leg – but nothing to save it!”

George Bernard Shaw

# The diabetic foot – a clinical challenge

Diabetes is a serious chronic disease that needs attention. Approximately 15% of all people with diabetes will be affected by a foot ulcer during their lifetime.<sup>1</sup>

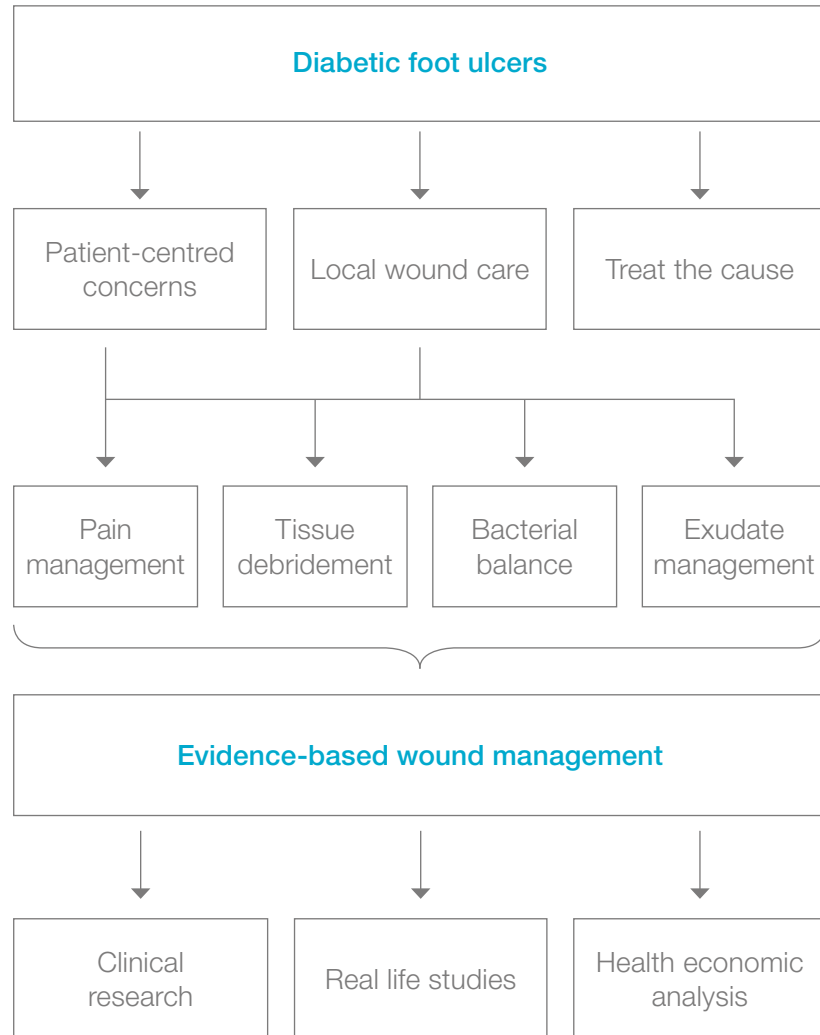
Diabetic foot ulcers (DFUs) often co-exist with vascular insufficiency and are the major cause of gangrene and amputation in people with diabetes. Risk of developing diabetic foot ulcers is greatly increased by reduced sensation and blood pressure.

Diabetic foot ulcers represent a huge risk to the patient’s quality of life, escalating wound/infection management and costs and account for a large proportion of all national healthcare budgets.

- Five-year recurrence rates of foot ulcers are 70%<sup>2</sup>
- Up to 85% of all amputations in relation to people with diabetes are preceded by a foot ulcer<sup>1-2</sup>
- People with diabetes with one lower limb amputation have a 50% risk of developing a serious lesion in the second limb within 2 years<sup>3</sup>
- People with diabetes have a 50% mortality rate in the 5 years following the initial amputation<sup>4</sup>

It is possible to reduce amputation rates by 49-85% through a care strategy that combines prevention, the interprofessional diabetes care team, appropriate organisation, close monitoring and education.<sup>1</sup>

# Pathway to clinical care and clinical evidence



# How to prevent DFUs

## Prevention and education

*"49-85% of all diabetic foot related problems are preventable."*

**Spraul, M., 2000.<sup>6</sup>**

*"This can be achieved through a combination of good foot care, provided by an interprofessional diabetes care team and appropriate education for people with diabetes."*

**Modified from Bakker, K. et al., 2005.<sup>1</sup>**

*"Education of patients, carers and healthcare providers is an essential component of an effective, interprofessional team approach, ...but effective systems and structures for screening, provision of chiropody and footwear and prompt treatment when required must be in place."*

**Modified from Spraul, M., 2000.<sup>6</sup>**

*"The most important aspects, for example, danger signs which require prompt action by the patient, should be summarized and repeated."*

**Spraul, M., 2000.<sup>6</sup>**

*"Successful diagnosis and treatment of patients with chronic wounds involve holistic care and a team approach. The integration of the work of an interprofessional care team that includes doctors, nurses and allied health professionals with the patient, family and caregivers offers an optimal formula for achieving wound resolution."*

**Sibbald, R.G., et al, 2001.<sup>18</sup>**

## Prevention of ulcer formation

People with diabetes must inspect their feet regularly, or have a family member or care provider do it on their behalf. Daily inspection is the foundation of diabetic foot ulcer prevention. All wounds and sores should be taken seriously early on.

Regular, gentle cleansing with soapy water, followed by the application of topical moisturizers, helps to keep the skin healthy and better able to resist breakdown and injury.

Shoes should be checked to ensure that they fit properly and offer adequate support. Consider athletic/sports shoes and thick, padded socks. Diabetic socks (unrestrictive on circulation) are also available. In the case of foot deformities or special support needs, custom shoes should be considered.

Minor foot injuries and infections, such as cuts, scrapes, blisters and tinea pedis (athletes foot), can be unintentionally worsened by home treatments that impede healing. Patients should be reminded to avoid hot soaks, heating pads and harsh topical agents such as hydrogen peroxide, iodine and astringents. A moist wound environment will help prevent ulcer formation. Minor wounds should be gently cleansed and treated with topical antiseptics. In addition, a physician should inspect any minor wounds that do not heal quickly.


By reinforcing preventive advice and inspecting the patient's feet at routine follow-ups, the physician can help the patient develop and maintain good foot-care practices.

## An interprofessional team approach

- Dietitian
- Diabetologist
- Pharmacist
- Family doctor/General practitioner
- Orthopaedic surgeon
- Rehabilitation team:
  - Occupational therapist
  - Physiotherapist or
  - Specialised physician
- Interventional radiologist
- Vascular surgeon
- Community nurse
- Dermatologist
- Orthotist
- Footcare specialist: Podiatrist

### Others

- Diabetes educator
- Psychologist
- Social worker
- Neurologist



The involvement of the patient as a member of the healthcare team improves patient care outcomes

# The patient's role

## Patient self-exam needs to be part of diabetic foot care and follow-up

Education of patient, family and healthcare providers, such as using an easy to understand patient leaflet for education, must be a priority.

- Any cut or open skin should be treated by a qualified healthcare provider immediately
- Inspect and examine the feet and shoes on a daily basis
- Appropriate footwear
- Nails should be cared for by a qualified foot specialist (podiatrist or related disciplines)
- Dry skin should be treated with appropriate moisturizing, such as (humectant) creams containing urea or lactic acid<sup>18</sup>
- Fungal infections, especially of the toe webs require topical antifungal agents

Patients should always remember to remove socks and shoes for regular inspection of both feet

# Consider the whole patient to ensure effective care of the foot ulcer

<b>Past history, medications and allergies</b>	Check for medications that may inhibit healing (i.e. steroids, immunosuppressants)
<b>Check for other complications</b>	Neurological, eye, heart, kidney, vascular
<b>Glycaemic* control</b>	Hb (Haemoglobin) A1c < 7.5% (depending on the specific situation of the patient, e.g. medication, risk of hypoglycemia, body weight)
<b>Hypertension* control</b>	< 140/90 mmHg
<b>Clinical obesity* control</b>	BMI < 30 kg/m <sup>2</sup>
<b>Hyperlipidemia* control</b>	Cholesterol < 5,2 mmol/L (200 mg/dL)

\*All 4 are associated with the metabolic syndrome and type 2 onset diabetes. Optimal control of diabetes will improve patient care outcomes.

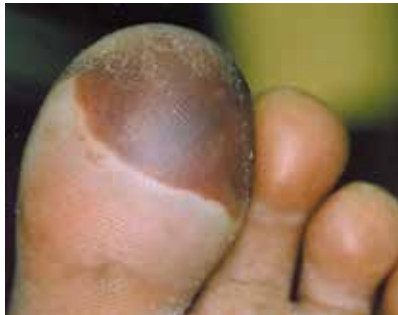Disclaimer:  
These are general guidelines. Please check local treatment recommendations applicable for your country or healthcare institution.

# How to diagnose and assess a diabetic foot ulcer

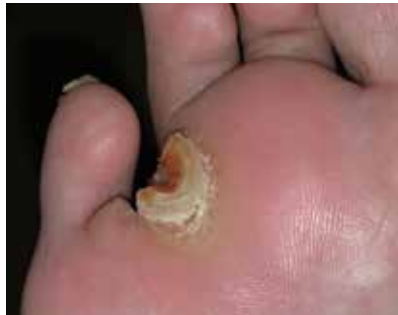“The VIPS”<sup>7,8</sup> of diabetic foot management to ensure outcomes

- V** Vascular supply is adequate
- I** Infection control is achieved
- P** Pressure offloading/downloading
- S** Sharp/surgical debridement has been considered

Diabetic foot ulcers typically have a thick rim of keratinised tissue surrounding the wound<sup>9</sup>



Blisters are associated with friction and shear

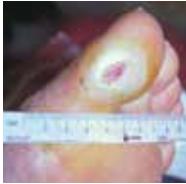

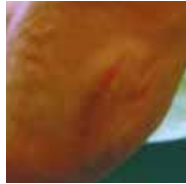


Callus is associated with increased pressure and haemorrhage

## Local wound assessment<sup>10</sup>

<b>History</b>	<ul style="list-style-type: none"> <li>· Previous ulcer(s), amputations</li> </ul>
<b>Local skin assessment</b>	<ul style="list-style-type: none"> <li>· Oedema</li> <li>· Colour</li> <li>· Temperature</li> <li>· Callus</li> </ul>
<b>Vascular examination</b>	<ul style="list-style-type: none"> <li>· Check for peripheral arterial disease Symptoms are often not found, but the following signs may be present: cold feet, blanching on elevation, absent hair growth, dry, shiny and atrophic skin<sup>9</sup></li> <li>· Palpate and check for dorsalis pedis, posterior tibial, popliteal and femoral pulses<sup>9</sup></li> <li>· Measure the ankle brachial pressure index (ABPI) Toe pressure or transcutaneous oxygen may be assessed, because arterial calcification can cause falsely elevated ABPI results<sup>9</sup></li> </ul>
<b>Neuropathy</b> <sup>8,11</sup>	<ul style="list-style-type: none"> <li>· Sensory – loss of protective sensation</li> <li>· Autonomic – lack of sweating that results in dry, cracked skin that bleeds and creates a portal of entry for bacteria</li> <li>· Muscular – loss of reflexes or atrophy of muscles that leads to foot deformities</li> </ul>
<b>Deformity and footwear</b>	<ul style="list-style-type: none"> <li>· Charcot foot</li> <li>· Hammer toes, claw toes, bunions</li> <li>· Check the deformity and address inappropriately fitted shoes</li> </ul>

## Types of neuropathy<sup>10</sup>

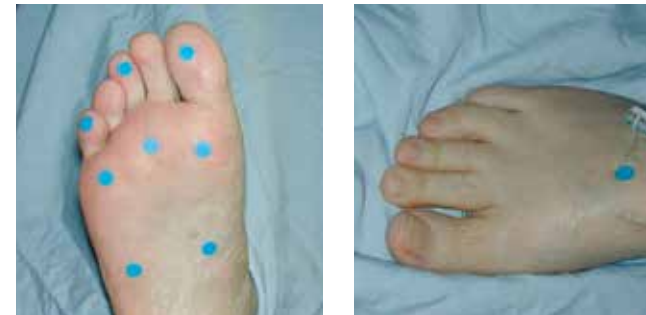Etiology	Sensory neuropathy	Autonomic neuropathy	Motor neuropathy
<b>Characteristics</b>	<ul style="list-style-type: none"> <li>· Loss of protective sensation</li> <li>· No perception of shoes rubbing or temperature changes</li> </ul>	<ul style="list-style-type: none"> <li>· Reduced sweating results in dry cracked skin</li> <li>· Increased blood flow leads to a warm foot</li> </ul>	<ul style="list-style-type: none"> <li>· Dysfunction of the motor nerves that control the movement of the foot. Limited joint mobility may increase plantar pressure</li> <li>· Foot deformities develop</li> <li>· Hammer toes</li> </ul>
<b>Clinical presentations</b>	<ul style="list-style-type: none"> <li>· Unaware of a foot ulcer or lack of discomfort when a wound is being probed</li> </ul>	<ul style="list-style-type: none"> <li>· Dry skin with cracks and fissures</li> <li>· Bounding pulses</li> <li>· Dilated dorsal veins</li> <li>· Warm feet</li> </ul>	<ul style="list-style-type: none"> <li>· High medial longitudinal arch, leading to prominent metatarsal heads and pressure points over the plantar forefoot</li> <li>· Clawed toes</li> <li>· Altered gait</li> </ul>
			

## 10g monofilament testing

The 10g monofilament testing is recommended as a screening tool to determine the presence of protective sensation in people with diabetes.<sup>11-13</sup>

### Places for testing

- Plantar surface of the metatarsal heads (min. 3 metatarsal heads)<sup>12,13</sup>
- The great toe/first toe<sup>12</sup>
- The medial and lateral sides of the plantar aspect of the midfoot<sup>13</sup>
- The plantar area of the heel<sup>13</sup>
- The dorsal aspect of the midfoot<sup>13</sup>



The pictures show testing sites

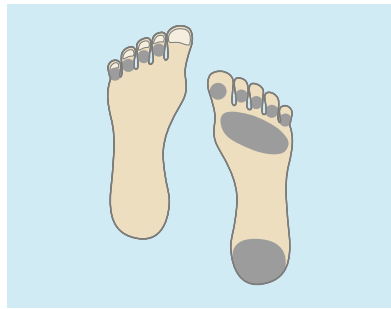*"There is no clear evidence on how many negative response sites equals an at-risk foot. Some literature shows that even one site with a negative response on each foot may indicate an at-risk foot."*

**Baker, N. et al., 2005.<sup>12</sup>**

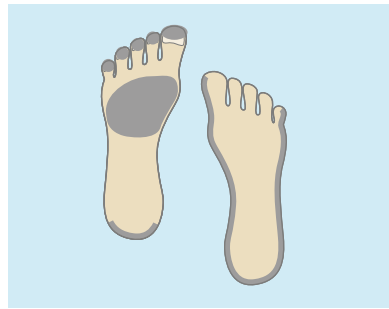

## Areas at risk for neuropathic, ischaemic and neuro-ischaemic ulcers

In a cross-sectional, population-based study the proportion of the lesions were\*2



Neuropathic ulcers 55% of total diabetic foot ulcers



Ischaemic ulcers 10% and neuro-ischaemic ulcers 34% of total diabetic foot ulcers

*“Recent experience from our clinic indicates that the frequency of neuropathic ulcers has decreased and the incidence of ischaemic and neuro-ischaemic ulcers has increased, equaling 50-50%.”*

**Mike Edmonds, 2005.**

\*1% of the ulcers were considered not to be diabetes-related.

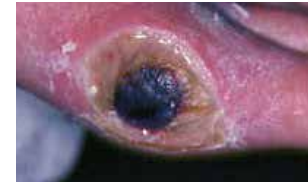## Clinical symptoms of neuropathic and ischaemic foot ulcers<sup>14</sup>

Clinical signs	Neuropathic ulcer 	Ischaemic ulcer 
Foot deformities	Clawed toes, possible high arch, possible Charcot deformities	No specific deformities. Possible absent toes/forefoot from previous amputations
Foot temperature/foot pulse	Warm, palpable pulse	Cold or decreased temperature, pulse may be absent or reduced
Skin colour	Normal or red	Pale/bluish. Pronounced redness when lowered (dependent rubor), blanching on elevation
Skin condition	Dry skin due to decreased sweating	Thin, fragile and dry
Ulcer location	On the plantar aspects (forefoot 80%) of the foot/toes	Distal/tips of the toes, heel, or margins of the foot
Callus present	Commonly seen on the weight-bearing areas and is generally thick	Not usually. If present, distal eschar or necrosis
Ulcer characteristics	Usually painless, with a “punched out” appearance (granulation or deeper base) surrounded by callus	Painful, especially with necrosis or slough
Sensation	Reduced or absent sensation to touch, vibration, pain, and pressure	Sensation may be present but decreased if there is associated neuropathy
Ankle reflexes	Usually not present	Usually present
Foot pulses	Present and often bounding. Dilated, prominent veins	Absent or markedly reduced

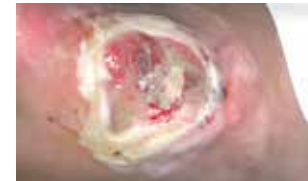## Ulcer assessment

<b>Neuropathic pain</b>	Burning, stinging, shooting and stabbing (non-stimulus dependent)
<b>Local pain</b>	Deep infection or Charcot joint
<b>Size</b>	Length, width, depth and location, preferably with clinical photograph
<b>Wound bed</b>	<b>Appearance</b> <ul style="list-style-type: none"> <li>· Black (necrosis)</li> <li>· Yellow, red, pink</li> <li>· Undermined</li> </ul>
<b>Infection signs</b>	<b>Odour</b> Be aware that some signs (fever, pain, increased white blood count/ ESR) may be absent. Evaluate the ulcer for signs of infection, inflammation and oedema. For more information, please see page 20
<b>Exudate</b>	Copious, moderate, mild, none
<b>Wound edge</b>	Callus and scale, maceration, erythema, oedema

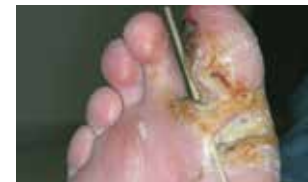## Wound bed



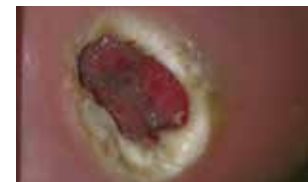Necrosis



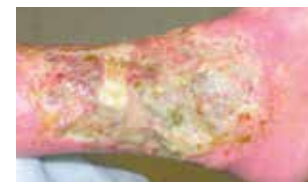Sloughy



Wound undermining, deep tissue infection



Maceration

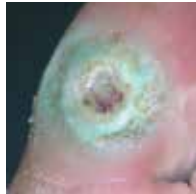

Unhealthy wound edge

## Superficial and deep infection symptoms<sup>10,15,16</sup>

### Superficial (local) – Treat topically

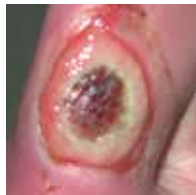- Non-healing
- Exuberant friable granulation tissue
- Bright red discoloration of granulation tissue
- Increased exudate
- Malodour
- New slough in wound base



Topical antimicrobial treatment may be considered for superficial/local infection, dependent on the assessment that will direct the treatment. Superficial/local infection may, however, require systemic antibiotics. For further details and updates, please see the International Consensus on the Diabetic Foot, 2011.<sup>2</sup>

### Deep – Treat systemically

- Pain
- Probes to bone (increased risk in the presence of osteomyelitis)
- New areas of break-down
- Warmth
- Erythema, oedema



Signs of local and deep infection are potentially limb and/or life threatening. These clinical signs and symptoms require urgent medical attention<sup>11</sup>

## Wagner classification

Grade	Ulcer appearance
Grade 0	No open lesions; may have deformity or cellulitis
Grade 1	Superficial diabetic ulcer (partial or full thickness)
Grade 2	Ulcer extension to ligament, tendon, joint capsule, or deep fascia without abscess or osteomyelitis
Grade 3	Deep ulcer with abscess, osteomyelitis or joint sepsis
Grade 4	Gangrene localised to portion of forefoot or heel
Grade 5	Extensive gangrenous involvement of the entire foot

Further reading:  
International Consensus on the Diabetic Foot, The International Working Group on the Diabetic Foot, 2011<sup>2</sup>, [www.iwgdf.org](http://www.iwgdf.org)

# How to treat a diabetic foot ulcer

## Treatment of diabetic foot ulcers

<b>Vascular</b>	<ul style="list-style-type: none"> <li>· If inadequate circulation, refer to vascular assessment and investigations</li> <li>· Consider angioplasty, bypass or amputation</li> </ul>
<b>Infection</b>	<p><i>Bacterial swabs help to identify organisms and sensitivity but do not diagnose infection in isolation from clinical features</i></p> <ul style="list-style-type: none"> <li>· Superficial/local – consider topical antimicrobial treatment (e.g. sustained silver releasing dressings). However, it may need systemic antibiotic therapy. The general treatment may also include debridement of devitalized tissue, pressure relief, optimising metabolic control and vascular intervention<sup>2</sup></li> <li>· Deep – requires systemic antibiotic therapy to initially cover Gram-positive, Gram-negative and anaerobic organisms. Subsequently, systemic antibiotic therapy can be modified according to the results of the culture. In addition, it is essential to consider the need for surgical debridement, drainage of infection alongside pressure relief and optimising metabolic control</li> <li>· Topical antimicrobial (e.g. sustained silver-releasing dressings) may give added benefit together with systemic coverage for deep infection</li> </ul>
<b>Pressure</b>	<ul style="list-style-type: none"> <li>· Appropriate offloading must be provided</li> <li>· Total contact cast or pneumatic walker</li> <li>· Deep toed or special shoes and orthotics</li> </ul>

Frequent (dependent on the clinical situation) inspection of the diabetic foot ulcer is vital due to the increased risk of infection

Disclaimer: These are general guidelines. Please check local treatment recommendations applicable for your country or healthcare institution.

## Local wound treatment

<b>Tissue debridement</b>	<ul style="list-style-type: none"> <li>· Sharp surgery preferred</li> <li>· Hydrogels, alginates and enzymes</li> <li>· Biosurgery</li> </ul>
<b>Infection</b>	<p>Dependent on the outcomes of the wound assessment:</p> <ul style="list-style-type: none"> <li>· Topical antimicrobials (e.g. sustained silver releasing dressings)</li> <li>· Systemic antibiotic therapy</li> </ul>
<b>Exudate management</b>	<ul style="list-style-type: none"> <li>· Foams, alginates</li> </ul>
<b>Management</b>	<ul style="list-style-type: none"> <li>· The treatment of the edge depends on the outcomes of the assessment of the edge of the wound. In general, healthy wounds have a pink woundbed and an advancing wound margin, while un-healthy wounds have a dark and undermined wound margin<sup>11</sup></li> </ul>
<b>Neuropathic pain</b>	<p>Occasionally, neuropathy can be associated with pain. For people with painful diabetic neuropathy, consider the following treatment:</p> <p>Tricyclic antidepressants<sup>7,17</sup> (TCAs):</p> <ul style="list-style-type: none"> <li>· Second generation TCA agents<sup>17</sup> e.g. duloxetine</li> <li>· First generation TCA agent<sup>7,17</sup>: amitriptyline</li> <li>· Anticonvulsants: pregabalin<sup>17</sup></li> </ul>

Application of moisture retentive dressings in the context of ischaemia and/or dry gangrene can result in a serious life-or-limb-threatening infection<sup>11</sup>

Infection control is of paramount importance in DFU treatment because of its strong association with amputation. A study of 1,666 patients with diabetes found that foot infection increased the risk of amputation by 155 times<sup>19</sup>

Disclaimer: These are general guidelines. Please check local treatment recommendations applicable for your country or healthcare institution.

# Case study

## Diabetic foot saved from amputation – 10 months treatment with Biatain® Ag Non-Adhesive foam dressing

**Authors: Juan Miguel Aranda, Monica Alcaide, José Manuel Sanchez Primary health care nurses. CAP Sant Llátzer del Consorci Sanitari de Terrassa (Barcelona).**

### Introduction

A breach in the skin caused by an ulcer is a portal for the entry of germs. In diabetics, the diminished response of white blood cells in quantitative and qualitative terms fosters infection. Aggravation and loss of feeling means that the patient may walk on infected tissue without being aware of it. This may escalate to more serious levels, worsening the condition of the wound and the patient. 40-50% of diabetic patients develop ulceration of the foot in the course of their life and of those, 14-20% experience amputation.

An ulcerated diabetic foot is a foot with suppuration, malodour, local necrosis, associated with two or more signs of perilesional inflammation (reddening, heat, pain, induration, pain when pressed), or osteomyelitis proved by imaging. Other causes of inflammation must be eliminated such as Charcot's neuro-arthropathy, breaks, thrombophlebitis, gout, lipoderm atosclerosis, etc.

A highly complex case of a diabetic foot calling constituting a major challenge for the nursing team is set out below. For all treatment, it is crucial to follow a personal care plan that coordinates the actions of all the members of the multidisciplinary medical history team. The success in this case was the result of perseverance by the team combined with the actions of family members and the effectiveness of the materials used.

### Medical history

Suffering from heart failure, coronary heart disease, arterial hypertension and venous insufficiency in both lower limbs, as well as Alzheimer's. Not suffering from dislipemia or drug allergies. For four months, she had a very deep wound on the right foot with erythema, oedema, crepitation and heat in the surrounding tissues. It should be pointed out that the patient was not aware of the seriousness of the process since she was suffering from disorientation in space and time and was in a wheelchair. She was referred to the A&E department and after examination by Vascular Surgery, her family was informed that the immediate treatment would involve supracondylar amputation since she was suffering from a grade 4-5 diabetic foot (Figure 1) based on the Wagner scale. The family was opposed to this treatment and the patient was returned to her home for monitoring by her family doctor and out-patient care and dressing by home nursing.

### Materials used

Biatain Ag foam dressings are highly absorbent, soft and conformable antibacterial polyurethane foam dressings that provide an optimal moist wound healing environment and effective exudate management.

Biatain Ag combines superior absorption with controlled and continuous silver release, at an effective rate. An antibacterial ionic silver complex is homogeneously dispersed within the foam and silver ions are released to the wound bed when wound exudate is absorbed into the dressing.

Biatain Ag foam dressings are protected with semi-permeable top films that are waterproof and provide bacterial barriers.

Biatain Ag Non-Adhesive foam dressings are suitable for use on fragile skin due to the absence of adhesive.

### Wound Progress

Once the diagnosis of grade 4-5 infected diabetic foot had been confirmed, systematic treatment with oral antibiotics monitored by the family doctor and strict temperature control, carried out by family members, was started to prevent the risk of generalised septicaemia. A daily home care plan for the nursing team was drawn up calling for a high degree of consistency, patience and dedication, and counting on the family's commitment to cooperation in the light of the risk of amputation. The care began with mechanical debridement and extraction of part of the necrotic, slough and suppurative skin and was then treated with enzymatic and autolytic debridements. The dressing used from the beginning was Biatain Ag due to the good exudate management properties and antimicrobial properties in one dressing.

Additionally Biatain Ag had the right density to alleviate pressure. When the treatment was first started, an alginate was used in the cavities to ensure effective management of the exudate and prevent maceration of the edges.

### Conclusion

The objective set was to prevent amputation of the foot, ensure the wellbeing and comfort of the patient and of the family. The method used began to bear fruit already seven days after the treatment started, with visible changes in the development of the wound. Analytical and culture checks were carried out regularly to ensure exhaustive monitoring of the infection, glycaemia and other analytical values to ensure proper planning and performance of the ongoing care. The wound closed ten months after the treatment was started.



Figure 1. The ulcer at inclusion.

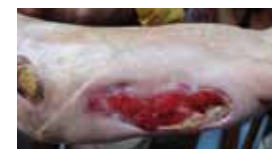

Figure 2. The ulcer after 5 weeks treatment.

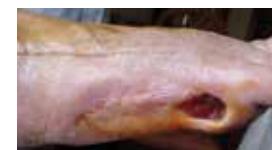

Figure 3. The ulcer after 4 months treatment.

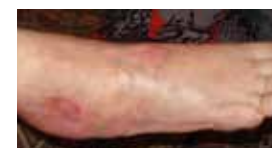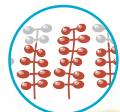


Figure 4. Closed ulcer after 10 months treatment

## Coloplast solutions for diabetic foot ulcers

### Biatain® Adhesive – superior absorption for faster wound healing

Biatain is a soft and conformable foam dressing that effectively absorbs and retains wound exudate.<sup>20,21</sup> This ensures a moisture balance that is optimal for healing of exuding wounds.<sup>22,23</sup>



Unique 3D polymer structure



### Biatain Non-Adhesive – superior absorption for wounds with extra fragile skin

Biatain Non-Adhesive is a soft and flexible absorbent polyurethane foam dressing with bevelled edges



### Biatain Silicone – superior absorption for general purposes

Biatain Silicone is a soft and flexible absorbent foam dressing with a gentle silicone adhesive only on the border leaving the foam free to absorb exudate and heal the wound



### Biatain Soft-Hold – superior absorption for wounds that are difficult to bandage

Biatain Soft-Hold has a gentle adherent layer covering less than 50% of the foam surface, allowing both hands to be free during dressing application and removal



### Biatain® Alginate – superior absorption for slough and cavity filling

Highly absorbent alginate dressing for moderately to heavily exuding wounds. Faster wound healing by conforming to any wound size/shape and by debridement of slough



### Purilon® Gel – faster wound healing by effective and gentle debridement


- Fast and effective debridement
- High cohesion – the gel stays in place

## Coloplast antimicrobial dressings for infected diabetic foot ulcers and ulcers at risk of infection

### Biatain® Ag Adhesive – superior absorption for infected wounds

Sustained release of silver during the entire wear time (up to 7 days)<sup>25</sup>

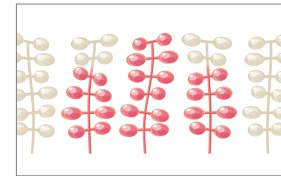
- Optimal healing environment<sup>26-27</sup>
- Rapid killing of bacteria<sup>28</sup>
- Designed to prevent wound infection



### Biatain Ag Non-Adhesive – superior absorption for infected wounds with extra fragile skin

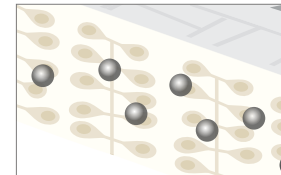
Biatain Ag is a soft and conformable silver foam dressing that is proven to help infected wounds heal faster<sup>26,27</sup>

## Mode of action



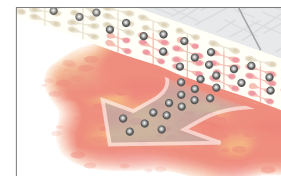
### Optimal healing environment<sup>26,27</sup>

- Unique 3D polymer foam
- Superior absorption and high retention



### Designed to prevent wound infection<sup>26-28</sup>

- Patented silver profile
- Sustained release of silver into the wound (up to seven days)




### Rapid killing of bacteria<sup>28,29,30</sup>

- Optimal concentration of silver
- Faster killing of bacteria in wound and dressing (e.g. MRSA, VRE, ESBL, Pseudomonas)


# Biatain® – superior absorption for faster healing

Superior absorption for non-infected wounds\*


## Biatain Silicone

	Item no.
 7.5x7.5	33434
10x10	33435
12.5x12.5	33436
15x15	33437
17.5x17.5	33438


## Biatain Soft-Hold

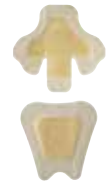	Item no.
 10x10	3470
10x20	3472
15x15	3475

## Biatain Non-Adhesive

	Item no.
 5x7	6105
10x10	3410
10x20	3412
15x15	3413
20x20	3416


## Biatain Adhesive

	Item no.
 7.5x7.5	3462
12.5x12.5	3420
18x18	3423
23x23 Sacral	3485
19x20 Heel	3488




Superior absorption for infected wounds

## Biatain Ag Non-Adhesive


	Item no.
 5x7	5105
10x10	9622
15x15	9625
5x8 Cavity	9628

## Biatain Ag Adhesive


	Item no.
 7.5x7.5	9631
12.5x12.5	9632

Other Coloplast Products for diabetic foot ulcers

## Biatain® Alginate


	Item no.
 5x5	3705
10x10	3710
15x15	3715
40cm/2g	3740

## Purilon® Gel

	Item no.
 8 g	3906
15 g	3900

Superior absorption for painful wounds

## Biatain Ibu Non-Adhesive

	Item no.
 10x10	34110
10x20	34112
15x15	34115
20x20	34120

\* Can be used for all types of exuding wounds.



# References

1. Bakker, K. et al. The year of the diabetic foot, *Diabetes Voice*, March 2005, Vol. 50(1): 11-14.
2. International Working Group on the Diabetic Foot, *International Consensus on the Diabetic Foot*, 2007, 2011.
3. Jude, E. et al. Assessment of the diabetic foot. *Chronic Wound Care: Chapter 58*, In: Krasner, D.L. et al., *A Clinical Sourcebook for Healthcare Professionals, Third Edition*, HMP Communications Inc. 2001: 589-597.
4. Armstrong, D.G. et al. Diabetic foot infections: stepwise medical and surgical management. *International Wound Journal*, 2004, Vol. 1(2): 123-132.
5. Williams, R. et al. The size of the problem: Epidemiological and economic aspects of foot problems in diabetes. In: Boulton, A.J.M. et al., *The Foot in Diabetes*, John Wiley & Sons, Ltd., 2000: 3-17.
6. Spraul, M. Education – can it prevent diabetic foot ulcers and amputations? In: Boulton, A.J.M. et al., *The Foot in Diabetes*, John Wiley & Sons, Ltd., 2000: 111-120.
7. Reddy, M. Wound healing: The next millennium. *Diabetic Microvascular Complications Today*, May/June 2005: 25-27.
8. Inlow, S. et al. Best practices for the prevention, diagnosis, and treatment of diabetic foot ulcers, *Ostomy/Wound Management* 2000, Vol. 46(11): 55-68.
9. Frykberg, R.G. et al. A summary of guidelines for managing the diabetic foot. *Advances in Skin & Wound Care* 2005, Vol. 18(4): 209-213.
10. Edmonds, M. et al. *A Practical Manual of Diabetic Foot Care*, Blackwell Science, Oxford 2004.
11. Registered Nurses' Association of Ontario 2005. *Assessment and management of foot ulcers for people with diabetes*. Toronto, Canada: Registered, Nurses' Association of Ontario.
12. Baker, N. et al. A user's guide to foot screening. Part 1: Peripheral neuropathy, *The Diabetic Foot* 2005, Vol. 8(1): 28-37.
13. Browne, A.C. et al. The diabetic neuropathic ulcer: An overview. *Ostomy/Wound Management*, 1999. Vol. 45 (No. 1A: Suppl).
14. Edmonds, M.E. et al. *Managing the Diabetic Foot*, Blackwell Science, Oxford 2005.
15. Sibbald, R.G. et al. Preparing the Wound Bed 2003: Focus on infection and inflammation, *Ostomy/Wound Management*, November 2003, Vol. 49(1): 24-51.
16. Sibbald, R.G. et al. Cost-effective faster wound healing of critically colonized wounds with a sustained release silver foam dressing, based upon the symposium "Bacteria, sustained release of silver and improved healing", An official satellite symposium of the WUWHS 2004. Published at [www.worldwidewounds.com](http://www.worldwidewounds.com) December 2005.
17. CG96 Neuropathic pain - pharmacological management: full guideline, NHS, National Institute for Health and Clinical Excellence, 27 May 2010 (<http://guidance.nice.org.uk/CG96/Guidance/pdf/English>).
18. Sibbald, R.G. et al. Dermatological aspects of wound care, Chapter 30, In: Krasner, D.L. et al., *A Clinical Sourcebook for Healthcare Professionals, Third Edition*, HMP Communications Inc., 2001: 273-285.
19. Lavery et al. *Diabetes Care* 2006;29(6):1288-93.
20. Andersen et al. A randomized, controlled study to compare the effectiveness of two foam dressings in the management of lower leg ulcers. *Ostomy/Wound Management* 2002;48(8):34-41.
21. Thomas et al. [www.dressings.org/TechnicalPublications/PDF/Coloplast-Dressings-Testing-2003-2004.pdf](http://www.dressings.org/TechnicalPublications/PDF/Coloplast-Dressings-Testing-2003-2004.pdf)
22. White R and Cutting KF. Modern exudate management: a review of wound treatments. *WorldWideWounds* 2006.
23. Romanelli et al. Exudate management made easy. *Wounds International* 2010;1(2).
24. Pham et al. A prospective, randomized, controlled double-blind study of a moisturizer for xerosis of the feet in patients with diabetes. *OstomyWound Management* 2002;48(5):30-36.
25. Buchholtz. An in-vitro comparison of antimicrobial activity and silver release from foam dressings. *Wounds UK* 2009.
26. Jørgensen et al. The silver-releasing foam dressing, Contreet Foam, promotes faster healing of critically colonised venous leg ulcers: a randomised, controlled trial. *International Wound Journal* 2005;2(1):64-73.
27. Münter et al. Effect of a sustained silver-releasing dressing on ulcers with delayed healing: the CONTOP study. *Journal of Wound Care*. 2006;15(5):199-206.
28. Ip et al. Antimicrobial activities of silver dressings: an in vitro comparison. *Journal of Medical Microbiology* 2006;55:59-63.
29. Basterzi et al. In-vitro comparison of antimicrobial efficacy of various wound dressings. *Wounds* July 2010.
30. Schwarzkopf et al. The release of silver ions from foam dressings. *Wound Management* January 2010.

